

Surgical Management of Submandibular Gland Sialolithiasis: A Case Report

Davi Barbosa Portela ^{1,*}, Josfran da Silva Ferreira Filho ¹, Eduardo Ribeiro Sampaio ², Bruna Salgado Piato Souza ³, Larissa Betina Alves Escobar ⁴, Radamés Bezerra Melo ¹, Maria Fabiane Parente Martins ⁵

¹ Paulo Picanço College, Fortaleza, Brazil.

² School of Pharmacy, Dentistry and Nursing, Federal University of Ceará, Fortaleza, Brazil.

³ University of Várzea Grande, Várzea Grande, Mato Grosso, Brazil.

⁴ Anhanguera College of Applied Social Sciences of Sinop, Sinop, Mato Grosso, Brazil.

⁵ Federal University of Ceará, Sobral, Ceará, Brazil.

* Correspondence: daviportela@hotmail.com.

Citation: Portela DB, Ferreira Filho JS, Sam-paio ER, Souza BSP, Escobar LBA, Melo RB, Rocha MN. Surgical Management of Submandibular Gland Sialolithiasis: A Case Report. Brazilian Journal of Case Reports. 2025 Jan-Dec;05(1):bjcr89.

<https://doi.org/10.52600/2763-583X.bjcr.2025.5.1.bjcr89>

Received: 20 March 2025

Accepted: 17 May 2025

Published: 22 May 2025



Copyright: This work is licensed under a Creative Commons Attribution 4.0 International License (CC BY 4.0).

Abstract: Sialolithiasis is an inflammation caused by the obstruction of a salivary gland's excretory system due to the formation of calculi. These mineralized structures occur mainly in the major salivary glands, particularly in the submandibular gland, due to the higher viscosity of saliva and increased concentrations of calcium and phosphate. The formation of sialoliths involves factors such as low salivary flow, infections, dehydration, and pH alterations, which lead to solute crystallization. Treatment aims to remove the sialolith; when the calculus is small and located near the duct opening, duct dilation and gland massage may result in its expulsion. However, if these conditions are not met, surgical removal becomes necessary. This case report describes a 26-year-old patient who presented to an Oral Surgery service with persistent pain in the submandibular region caused by a sialolith. Despite the absence of radiographic examination, the presence of a calculus in the submandibular duct was confirmed clinically. Surgery was performed under local anesthesia, resulting in successful removal of the sialolith. Postoperative medication and care instructions were provided. Despite the prolonged nature of the condition, the treatment yielded satisfactory results, with no signs of complications or recurrence.

Keywords: Salivary Gland Calculi; Submandibular Gland; Oral Surgery.

1. Introduction

Sialolithiasis is an inflammatory reaction caused by obstruction of the excretory system of a major or minor salivary gland, leading to saliva retention. It is characterized by the formation of calculi within the duct of a salivary gland, most commonly affecting the submandibular gland [1–3]. This obstruction arises from a mineralized structure known as a salivary calculus or sialolith. These structures are predominantly formed in the major salivary glands, especially the submandibular gland. A sialolith is defined as a concretion within a salivary gland or its main duct, visible to the naked eye. Sialoliths form through the crystallization of salivary solutes, influenced by factors such as reduced salivary flow, oropharyngeal infections, dehydration, obstruction, and changes in salivary pH, which affect crystalloid solubility and increase their concentration. Salivary stones grow by concentric deposition at an approximate rate of 1 mm per year, with a mineral content composed of various forms of calcium phosphate interspersed with less dense organic matter, including cellular debris, proteins, and microorganisms [4,5].

The submandibular gland is more susceptible to sialolithiasis than other salivary glands due to its anatomical and physiological characteristics. Approximately 60–90% of sialoliths are found in the submandibular gland, while the remainder occur in the parotid gland, with the sublingual glands rarely affected. Submandibular saliva is more alkaline and contains higher concentrations of calcium and phosphate, mainly in the form of carbonates. In addition, the higher viscosity of submandibular saliva, due to its greater mucin content, promotes adhesion around foreign bodies. The submandibular duct also has a pronounced curvature of nearly 100 degrees upon exiting the gland, which facilitates retention. Because they are mineralized structures, sialoliths are readily visible on radiographic examinations. Periapical radiographs may reveal sialoliths, particularly when located in more superior regions; however, occlusal and lateral mandibular radiographs are recommended for locating calculi within the submandibular gland [3,5,6].

Treatment is aimed at removing the sialolith to resolve the obstruction and inflammation. In rare cases where the calculus is small and located near the opening of the excretory duct, catheterization and duct dilation may allow its expulsion. However, surgical removal is generally necessary. When the calculus is located in the anterior half of the submandibular duct, the procedure is relatively simple due to its submucosal location. In the posterior portion of the duct, surgery becomes more delicate due to anatomical relationships, particularly with the lingual nerve. In some cases, large segments of the duct must be excised. Attempts have been made to replace the duct with plastic tubes, promoting re-epithelialization and the formation of a new excretory channel, both in the parotid and submandibular glands. In advanced cases, complete gland removal may be required [7,8]. The rapid development of non-surgical and minimally invasive techniques has enabled greater gland preservation, such as endoscopic approaches with interventional sialography using endoscopes designed for salivary interventions, which vary in size and rigidity [7,9–11].

This clinical case report describes the surgical management of a sialolith in the submandibular gland, highlighting the approach and therapeutic conduct taken to achieve a satisfactory outcome.

2. Case Report

A 26-year-old male patient, systemically healthy, presented to the dental service with the chief complaint of swelling in the right sublingual and submandibular region. During anamnesis, the patient reported previous episodes of pain and edema in the same area; however, there had been no spontaneous expulsion of the sialolith nor prior surgical intervention. He denied any febrile episodes, and his past medical history was unremarkable. The patient had been referred from another dental service with only a prescription of amoxicillin 500 mg every 8 hours for 7 days.

Intraoral clinical examination revealed swelling in the right floor of the mouth, in the region of the Wharton's duct orifice. On palpation, a firm and mobile nodule was identified (Figure 1A). Compression of the submandibular and sublingual glands resulted in the discharge of purulent secretion from the Wharton's duct orifice (Figure 1B). Surgical exploration and manipulation of the area allowed visualization of the sialolith and confirmation of an active infectious process. As the procedure was performed on an emergency basis in a dental service that lacked occlusal radiographic film, complementary radiographic examinations could not be conducted. Therefore, the clinical diagnosis of sialolithiasis was established based on medical history and intraoral findings.

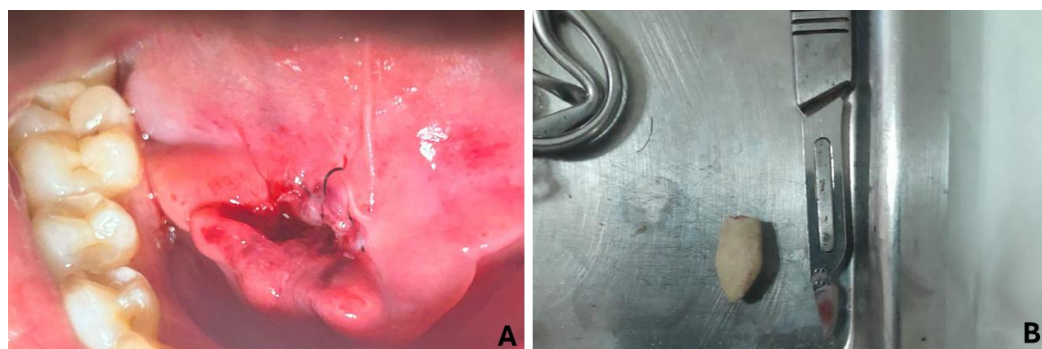
The proposed treatment was surgical removal of the sialolith through an intraoral approach under local anesthesia. Since spontaneous drainage was already occurring, simple medication and drainage alone would not resolve the condition due to the persistence of the causative factor. Initially, purulent secretion was drained. A small incision was then made in the floor of the mouth over the palpable calculus, preserving the sublingual caruncle. The duct was identified and carefully dissected until complete removal of the sialolith was achieved (Figure 2A). Suturing was performed with 4-0 nylon thread, limited to

the mucosa, in order to avoid ductal closure and postoperative salivary retention (Figure 2B).

Figure 1. A. Initial appearance of the lesion on the floor of the mouth, in the region of Wharton's duct. B. Discharge of purulent secretion from the orifice of Wharton's duct.

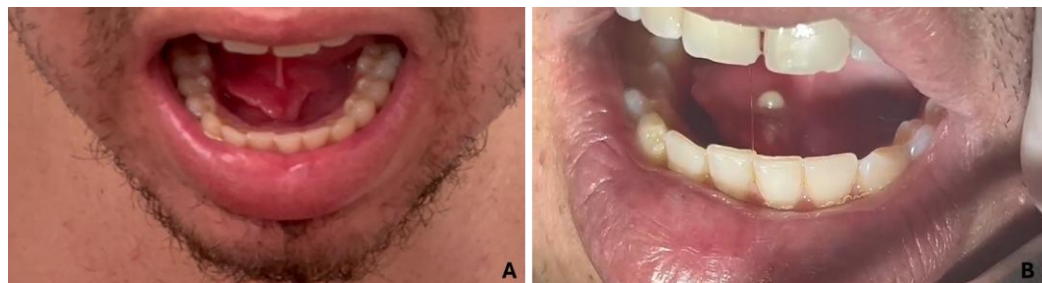

Figure 2. A. Final appearance of the lesion after excision and suturing. B. Appearance of the sialolith after excision.



The patient received detailed instructions regarding postoperative care and the correct use of prescribed medications. The medication protocol included amoxicillin 875 mg + potassium clavulanate 125 mg every 12 hours for 7 days; ibuprofen 600 mg every 8 hours for 3 days; and dipyron 500 mg every 6 hours for 3 days, all administered orally. Clinical follow-up was performed after 15 days (Figure 3A) and after 90 days (Figure 3B), with no signs of complications, confirming the success of the treatment approach. Postoperative radiographic or tomographic imaging was not performed due to the patient not returning for the suture removal appointment; however, clinical monitoring continued.

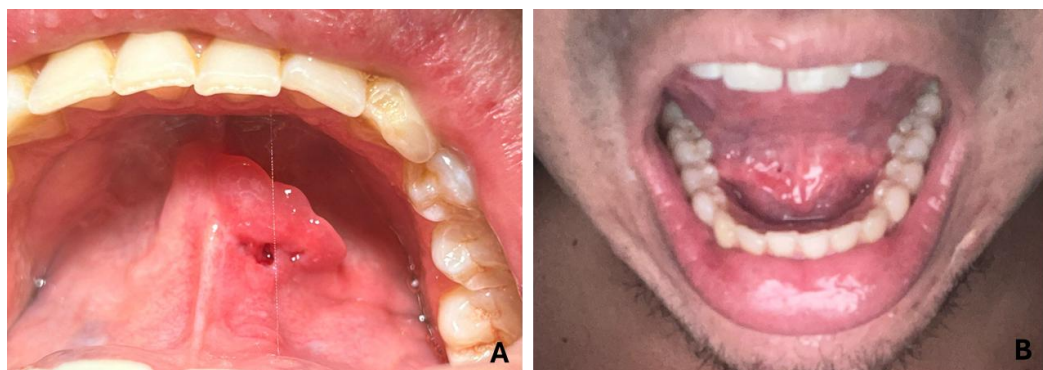3. Discussion

The submandibular gland, one of the major salivary glands, is a mixed gland with predominantly mucous secretion, located in relation to the mylohyoid muscle at the angle of the mandible [8]. Sialolithiasis, a condition characterized by the formation of calculi in the salivary ducts, is more prevalent in adult males and clinically presents with pain and swelling in the affected gland region, typically worsening during meals [1,8–11]. This benign condition, which involves the formation of sialoliths in the parotid, submandibular, and sublingual glands, is the most common cause of salivary gland swelling, with a reported incidence ranging from 1 in 10,000 to 1 in 30,000 individuals. In more severe cases, ductal obstruction can lead to inflammation (sialadenitis) or, rarely, abscess formation. The most common symptoms include cyclic postprandial swelling of the affected gland and reduced salivary flow [12–14].

The diagnosis of sialolithiasis depends on the location and size of the calculi. For larger sialoliths located in the distal portion of the submandibular duct (Wharton's duct), physical examination is often sufficient for diagnosis. However, smaller calculi in the dis-

tal submandibular or parotid duct (Stensen's duct) require more advanced imaging methods such as conventional radiography, sialography, ultrasound, computed tomography (CT), magnetic resonance imaging (MRI), or sialoendoscopy [14]. Occlusal radiography is the standard exam for detecting submandibular and lingual calculi, although not all calcifications are visible using conventional methods, which may necessitate more sensitive imaging techniques such as CT. In the present case, CT imaging was not feasible due to socioeconomic limitations, but occlusal radiography and clinical findings were sufficient for diagnosis and planning a minimally invasive surgical approach [11].

Figure 3. A. Final appearance 15 days postoperatively. B. Final appearance 90 days postoperatively, showing a satisfactory outcome with no signs of complications.



Treatment of sialolithiasis varies according to the size and location of the stones. Small and asymptomatic calculi may be managed conservatively with measures such as hydration, sialogogues, and gland massage. On the other hand, larger and symptomatic stones that obstruct salivary flow require surgical intervention [10]. The choice of surgical technique depends on the sialolith's location: calculi located in the anterior or middle third of the duct may be removed via intraoral surgical exploration, while those located more posteriorly may require sialoadenectomy [11].

With recent advances, minimally invasive techniques such as sialoendoscopy and lithotripsy have gained prominence, allowing for stone removal without gland resection. Sialoendoscopy is primarily used for large salivary calculi, while extracorporeal or endoscopic intracorporeal shock wave lithotripsy applies shock waves directly to the surface of the stone within the duct, sparing adjacent tissues. These approaches preserve salivary gland function and reduce the risks associated with more invasive procedures. Although minimally invasive techniques preserve glandular structures better than conventional surgery, their success depends directly on the surgeon's skill and the availability of appropriate instruments and equipment, which are often not accessible in the public healthcare system [9,12,13]. In the present case, intraoral surgical removal was successfully performed, demonstrating the effectiveness of this approach in selected cases.

Prophylactic or therapeutic antibiotic therapy is indicated in cases of associated infection, such as sialadenitis or abscess formation. In the present case, the presence of purulent discharge justified the prescription of amoxicillin combined with clavulanic acid to control the bacterial infection [7,9,10]. Additionally, the use of nonsteroidal anti-inflammatory drugs (NSAIDs) and analgesics was essential for managing postoperative pain and inflammation.

4. Conclusion

Sialolith removal in the submandibular gland can be performed effectively and safely, provided that it is preceded by thorough clinical and tomographic evaluation to ensure an accurate diagnosis and proper surgical planning. However, attention to technical aspects during the procedure, as well as appropriate postoperative management, is crucial to preserve the functionality of the salivary duct and prevent complications. In this

clinical case, the patient presented with persistent spontaneous purulent drainage and no clinical improvement with medication alone.

The persistence of symptoms, along with the risk of clinical deterioration, justified the immediate removal of the obstructive factor, reinforcing the importance of timely decision-making in acute presentations, even when ideal diagnostic resources are unavailable. Postoperative follow-up is essential to monitor recovery, prevent recurrence, and ensure that the patient remains asymptomatic and free of discomfort. This case highlights the importance of a specialized approach, using appropriate diagnostic tools and surgical techniques to optimize outcomes and minimize risks.

Funding: None.

Research Ethics Committee Approval: We declare that the patient provided written informed consent and that the study was conducted in accordance with the ethical guidelines outlined in the Declaration of Helsinki.

Acknowledgments: None.

Conflicts of Interest: The authors declare no conflicts of interest.

References

1. Gulati U, Singh S, Kaur R, Kaur H. Submandibular sialolithiasis: a brief overview and report of two cases. *Modern Res Dent.* 2018;1(5):1-7.
2. Holden AM, Adamson R, Davies-Husband C, Bentley R. Audit of minimally-invasive surgery for submandibular sialolithiasis. *Br J Oral Maxillofac Surg.* 2019;57(6):582-586.
3. Kolomiets SV, Melnichenko YM, Ivanova EV, Kravtsova OA. Difficulties in diagnosis of sialolithiasis: A case series. *Bull Tokyo Dent Coll.* 2018;59(1):53-58.
4. Sherman JA, McGurk M. Lack of correlation between water hardness and salivary calculi in England. *Br J Oral Maxillofac Surg.* 2000;38(1):50-53.
5. Diebold S, Overbeck M. Soft Tissue Disorders of the Mouth. *Emerg Med Clin North Am.* 2019;37(1):55-68.
6. Marchal F, Dulguerov P. Sialolithiasis management: the state of the art. *Arch Otolaryngol Head Neck Surg.* 2003;129(9):951-956.
7. Arifa SP, Muhammed S, Saleem S, Ravi MB. Sialolithiasis of the Submandibular Gland: Report of Cases. *Cureus.* 2019;11(3):4180.
8. Oliveira TP, Silva LF, Martins-Filho PR, Santos TS. Giant sialolith of submandibular gland duct treated by excision and ductal repair: a case report. *Braz J Otorhinolaryngol.* 2016;82(1):112-115.
9. Folchini S, Stolz AB. Sialoliths in the submandibular gland: a case report. *Odontol Clin-cient.* 2016;15(1):67-71.
10. Aisshwarya P, Sivapathasundharam B, Santhosh Kumar MP. Diagnosis and management of submandibular duct sialoliths: Report of 2 cases. *Nac J Med Den Res.* 2017;5(3):237-241.
11. Da Silva WG, de Souza Andrade ESS, de Oliveira Costa F, de Souza Figueiredo PT. Stafne's bone defect in a metastatic prostate cancer patient: A diagnostic conundrum. *J Clin Exp Dent.* 2018;10(1):88-91.
12. Huoh KC, Eisele DW. Etiologic factors in sialolithiasis. *Otolaryngol Head Neck Surg.* 2011;145(6):935-939. doi: 10.1177/0194599811415801.
13. Iqbal A, Gupta AK, Natu SS, Gupta AK. Unusually large sialolith of Wharton's duct. *Ann Maxillofac Surg.* 2012;2(1):70-73.
14. Rzymaska-Grala I, Stopa Z, Grala B, et al. Salivary gland calculi - contemporary methods of imaging. *Pol J Radiol.* 2010;75(3):25-37.